

## Use of the Intubating LMA-Fastrach™ in 254 Patients with Difficult-to-manage Airways

David Z. Ferson, M.D.,\* William H. Rosenblatt, M.D.,† Mary J. Johansen, Pharm.D.,‡ Irene Osborn, M.D.,§ Andranik Ovassapian, M.D.¶

**Background:** The laryngeal mask airway (LMA™; LMA North America, Inc., San Diego, CA) has a well-established role in the emergency and elective treatment of patients with difficult-to-manage airways (DA). In this study, the authors report their clinical experience with the intubating LMA (LMA-Fastrach™; LMA North America, Inc., San Diego, CA) in 254 patients with different types of DA.

**Methods:** The authors reviewed the anesthetic and medical records of patients with DA in whom the LMA-Fastrach™ was used electively or emergently at four institutions from October 1997 through October 2000. In each case, the number of insertion and intubation attempts was recorded. Success rates for blind and fiberoptically guided intubation through the LMA-Fastrach™ were calculated, up to a maximum of five attempts per patient.

**Results:** The LMA-Fastrach™ was used in 257 procedures performed in 254 patients with DA, including patients with Cormack-Lehane grade 4 views; patients with immobilized cervical spines; patients with airways distorted by tumors, surgery, or radiation therapy; and patients wearing stereotactic frames. Insertion of the LMA-Fastrach™ was accomplished in three attempts or fewer in all patients. The overall success rates for blind and fiberoptically guided intubations through the LMA-Fastrach™ were 96.5% and 100.0%, respectively.

**Conclusions:** The LMA-Fastrach™ was used successfully in a high percentage of patients who presented with a variety of DA. The clinical experience presented herein indicates that this device may be particularly useful in the emergency and elective treatment of patients in whom intubation with a rigid laryngoscope has failed and in the treatment of patients with immobilized cervical spines.

A CLOSED claims study published by the American Society of Anesthesiologists (ASA) in 1990 revealed the

significance of respiratory problems in anesthetized patients.<sup>1</sup> This study laid the groundwork for the development of the ASA Difficult Airway Algorithm, which established pathways for the care of patients with difficult-to-manage airways (DA).<sup>2</sup> Although initially, the ASA Difficult Airway Algorithm recommended the use of the laryngeal mask airway (LMA™; LMA North America, Inc., San Diego, CA) only in an emergency, Benumof<sup>3</sup> subsequently identified five main pathways in the algorithm in which the LMA™ may be used as a ventilating device and as a conduit for tracheal intubation. Using the LMA™ electively or emergently in patients with DA now represents a recognized alternative in all the pathways of the ASA Difficult Airway Algorithm.

In 1997, the intubating LMA (LMA-Fastrach™; LMA North America, Inc., San Diego, CA) was introduced. The LMA-Fastrach™ retains all of the ventilatory features of the classic LMA™ but is designed to provide a superior conduit for blind or fiberoptically guided tracheal intubations.<sup>4,5</sup> Reports evaluating the effectiveness of the LMA-Fastrach™ in the treatment of patients with DA have been limited.<sup>6,7</sup> In this article, we present the cumulative experience of four institutions with the use of the LMA-Fastrach™ in 254 patients with DA. In all cases, insertion of and intubation through the LMA-Fastrach™ were performed by investigators with extensive clinical experience using the classic LMA™ for the elective and emergency treatment of patients with DA. Before publication of this article, these investigators had begun using the LMA-Fastrach™ in their clinical treatment of patients with DA because of the superior characteristics of the device as a conduit for blind or fiberoptically guided intubations.

### Materials and Methods

After Institutional Review Board approval from all four institutions participating in this report, we reviewed the medical records and notes taken from the anesthetic records of patients in whom the LMA-Fastrach™ was used emergently or electively for intubating purposes from October 1997 through October 2000. The four institutions who participated in this report were The University of Texas M. D. Anderson Cancer Center (Houston, TX), Yale University School of Medicine (New Haven, CT), Mt. Sinai School of Medicine (New York, NY), and the University of Chicago (Chicago, IL).

The investigators, each of whom had been trained in LMA-Fastrach™ insertion and intubation techniques by

\* Associate Professor, Department of Anesthesiology, † Assistant Professor, Department of Experimental Therapeutics, The University of Texas M. D. Anderson Cancer Center. ‡ Associate Professor, Department of Anesthesiology, Yale University School of Medicine. § Associate Clinical Professor, Department of Anesthesiology, Mt. Sinai School of Medicine. ¶ Professor, Department of Anesthesia and Critical Care, The University of Chicago.

Received from the Department of Anesthesiology and the Department of Experimental Therapeutics, Division of Cancer Medicine, The University of Texas M. D. Anderson Cancer Center, Houston, Texas; the Department of Anesthesiology, Yale School of Medicine, New Haven, Connecticut; the Department of Anesthesiology, Mt. Sinai School of Medicine, New York, New York; and the Department of Anesthesia and Critical Care, The University of Chicago, Chicago, Illinois. Submitted for publication January 17, 2001. Accepted for publication June 8, 2001. Supported solely by the Department of Anesthesiology, The University of Texas M. D. Anderson Cancer Center; the Department of Anesthesiology, Yale School of Medicine; the Department of Anesthesiology, Mt. Sinai School of Medicine; and the Department of Anesthesia and Critical Care, The University of Chicago. Dr. Ovassapian has received both cash and equipment support from LMA North American Company, San Diego, California, for workshops conducted at Northwestern University, Chicago, Illinois, and the University of Chicago, and for the Airway Study and Training Center at the University of Chicago.

Address reprint requests to Dr. Ferson: Department of Anesthesiology, Box 42, The University of Texas M. D. Anderson Cancer Center, 1515 Holcombe Boulevard, Houston, Texas 77030. Address electronic mail to: dferson@mdanderson.org. Individual article reprints may be purchased through the Journal Web site, www.anesthesiology.org.

the inventor of the device, Dr. Archie Brain, performed all *LMA-Fastrach*<sup>TM</sup> insertions. Consequently, the same insertion and intubation techniques were used in every patient. Each of the clinicians also had previous experience with the use of the *LMA-Fastrach*<sup>TM</sup> in patients with normal airways before using it in patients with DA.

The investigators used the *LMA-Fastrach*<sup>TM</sup> in patients in whom intubation had previously proven to be difficult or was expected to be difficult based on the patient's underlying disease and physical findings. A history of gastroesophageal reflux or hiatal hernia precluded the elective use of the *LMA-Fastrach*<sup>TM</sup>. However, these exclusion criteria did not apply when the device was used for emergency airway management in patients with unexpected DA in whom other methods of securing the airway had failed.

For each case, the number of insertion and intubation attempts and the success or failure to establish ventilation and to achieve intubation were reviewed. Each patient's age, weight, height, and ASA physical status were obtained from the records, as were the locations where intubations were performed, the type of airway difficulty, the type of anesthesia used, and whether the Chandy maneuver was used (Dr. Chandy Verghese, Consultant in Anaesthesia and Intensive Care, Royal Berkshire Hospital, Reading, England, verbal communication, January 1998). Any complications that were documented as having occurred during *LMA-Fastrach*<sup>TM</sup> insertion and intubation were also reviewed.

#### *Insertion of the LMA-Fastrach*<sup>TM</sup>

As recommended in the *LMA-Fastrach*<sup>TM</sup> instruction manual,<sup>8</sup> the patient's head was placed in a neutral position during insertion by placing a support between the operating table and the occiput of the patient.<sup>8</sup> After insertion of the device, ventilation was confirmed by observing chest movement and capnography. The following anesthetic techniques for insertion of the *LMA-Fastrach*<sup>TM</sup> were identified.

For the majority of elective cases, in patients with no airway pathology, general anesthesia was induced with propofol (2.0–2.5 mg/kg).<sup>9</sup> In patients whose airways had been altered by tumors, surgery, or radiation therapy, inhalation induction with sevoflurane (2–4%) was used while spontaneous respiration was maintained. For patients in whom insertion of the *LMA-Fastrach*<sup>TM</sup> was performed while the patient was awake, topical anesthesia to the airway was achieved with 4% lidocaine spray to the oropharynx and 3–4 ml lidocaine, 4%, was injected through the cricothyroid membrane. Emergency insertions of the *LMA-Fastrach*<sup>TM</sup> were performed in unconscious patients outside the operating room and in anesthetized patients in the operating room in whom other techniques for intubation had failed.

In patients with unstable cervical spines, *LMA-Fastrach*<sup>TM</sup> insertion and intubation were performed

with rigid Philadelphia collars (Philadelphia Cervical Collar Co., Westville, NJ) in place. A small portion of the foam from the chin section of the Philadelphia collar was cut out to provide adequate access to the patient's mouth during *LMA-Fastrach*<sup>TM</sup> insertion and to allow for the correct insertion technique. As determined by the neurosurgeons before using the *LMA-Fastrach*<sup>TM</sup>, this modification did not affect stabilization of the neck.

#### *Intubation through the LMA-Fastrach*<sup>TM</sup>

Blind intubation through the *LMA-Fastrach*<sup>TM</sup> was attempted electively in patients with no intrinsic tumors distorting the airway. A nondisposable, silicone endotracheal tube (ETT; ILM Endotracheal Tube; Euromedical, Lake Zurich, IL) designed for blind intubation through the *LMA-Fastrach*<sup>TM</sup> was used in all patients. Water-soluble lubricant was applied to the ETT before insertion into the *LMA-Fastrach*<sup>TM</sup>.

A useful maneuver to aid the correct positioning of the *LMA-Fastrach*<sup>TM</sup> and to facilitate blind intubation was developed by Dr. Chandy Verghese (fig. 1). The Chandy maneuver consists of two steps, which are performed sequentially. The first step, which is important for the establishment of optimal ventilation, is performed by slightly rotating the device in the sagittal plane using the metal handle until the least resistance to bag ventilation is achieved. The second step of the Chandy maneuver is performed just before blind intubation and consists of using the metal handle to slightly lift (but not tilt) the *LMA-Fastrach*<sup>TM</sup> away from the posterior pharyngeal wall. This facilitates the smooth passage of the ETT into the trachea. Although all of the authors were aware of the Chandy maneuver, only one used it consistently in his clinical practice.

When the *LMA-Fastrach*<sup>TM</sup> is aligned with the glottic opening, little or no resistance is encountered when passing the ETT into the trachea. However, when resistance is encountered, the *LMA-Fastrach*<sup>TM</sup> instruction manual<sup>8</sup> recommends further manipulations to assist passage of the ETT. These manipulations are based on measuring how far the ETT has been advanced beyond the distal opening of the metal tube of the *LMA-Fastrach*<sup>TM</sup> when resistance is encountered. That distance can easily be calculated by counting the 1-cm markings above a black transverse mark on the ETT, which represents the point where the ETT emerges from the distal opening of the metal tube of the *LMA-Fastrach*<sup>TM</sup>. Based on the manual's recommendations, the investigators used the following guidelines for subsequent intubation attempts.

1. If resistance was felt after advancing the ETT 3 cm beyond the distal opening of the *LMA-Fastrach*<sup>TM</sup> tube, the device was too small, and a larger *LMA-Fastrach*<sup>TM</sup> was used.

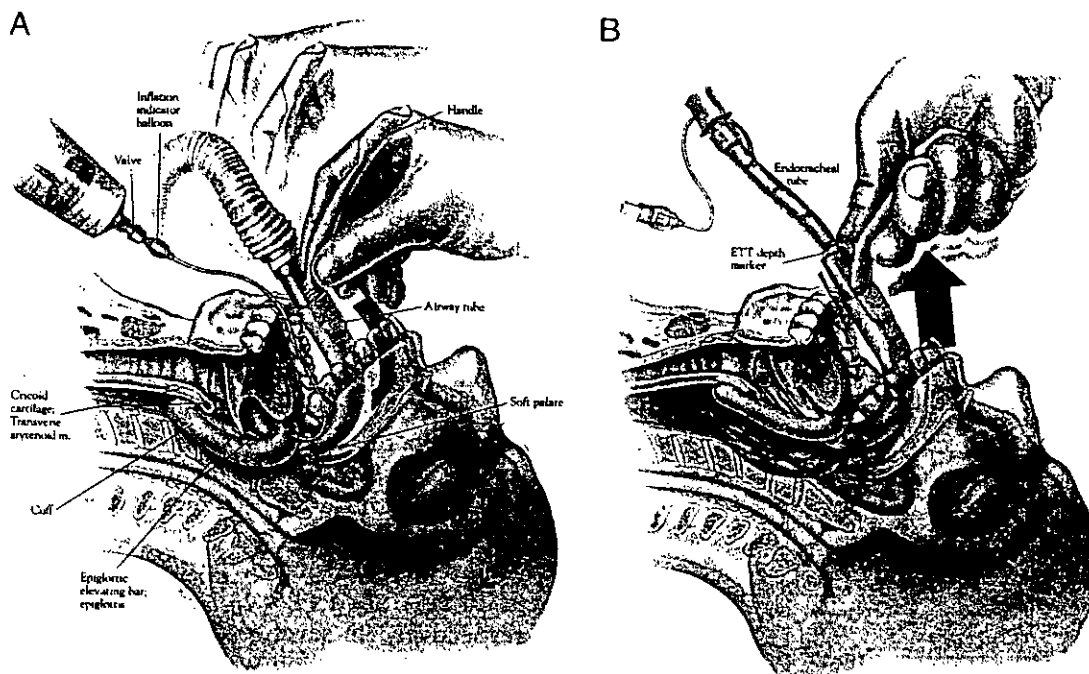


Fig. 1. (A) The two steps of the Chandy maneuver are performed sequentially. After insertion of the *LMA-Fastrach*™ (LMA North America, Inc., San Diego, CA), optimal ventilation is established by slightly rotating the device in the sagittal plane, using the metal handle, until the least resistance to bag ventilation is achieved. This helps to align the internal aperture of the device with the glottic opening. (B) Just before blind intubation, the *LMA-Fastrach*™ is slightly lifted (but not tilted) away from the posterior pharyngeal wall using the metal handle. This prevents the endotracheal tube (ETT) from colliding with the arytenoids and facilitates the smooth passage of the ETT into the trachea.

2. If resistance was felt within 1 cm when trying to advance the ETT, the device was too large, and a smaller *LMA-Fastrach*™ was used.
3. If resistance was felt 2-2.5 cm beyond the distal opening of the *LMA-Fastrach*™ tube, the epiglottis had become down-folded during insertion and was not within reach of the epiglottic elevating bar (EEB). In this case, the *LMA-Fastrach*™ was partially withdrawn and reinserted.

To avoid airway trauma, force was not used to overcome resistance when advancing the tracheal tube. In addition, the number of intubation attempts was limited to five, after which intubation was completed with the aid of a fiberoptic bronchoscope (FOB; Olympus LF-2, Olympus BF XT-30; Olympus America, Inc., Melville, NY).

Fiberoptically assisted intubation was chosen as the initial method of intubation in patients with airway tumors and in those whose airways had been altered by previous surgery or radiation therapy. During fiberoptically guided intubations through the *LMA-Fastrach*™, the FOB was initially kept inside the ETT. However, after the tip of the ETT reached and lifted the EEB, the FOB was advanced through the tip of the ETT and passed between the vocal cords into the trachea. The ETT was then advanced over the FOB until tracheal intubation was achieved.

#### Statistical Analysis

For each attempt to insert or intubate through the *LMA-Fastrach*™, success rates were calculated for all patients and for each type of DA. To analyze factors that influenced the success rates for insertion of and intubation through the *LMA-Fastrach*™, we used the Pearson chi-square test to compare independent proportions and reported the differences in proportions in terms of the odds ratio with corresponding 95% confidence intervals. A *P* value less than 0.05 was considered significant.

#### Results

The *LMA-Fastrach*™ was used for tracheal intubation on 257 occasions, which included 246 intubations (95.7%) performed in 243 patients in an operating room, 5 intubations (1.9%) in an emergency room, 4 intubations (1.6%) in a radiology suite, and 2 intubations (0.8%) in an intensive care unit (table 1).

According to the anesthesia and medical records, each patient had at least one of the following characteristics: (1) a failed intubation associated with a grade 4 laryngoscopic view as defined by Cormack and Lehane<sup>10</sup>; (2) an immobilized cervical spine; (3) a distorted airway secondary to tumor, surgery, or radiation therapy; or (4) the presence of a stereotactic head frame that limited access to the airway.

**Table 1. Demographic, Surgical, and Anesthetic Characteristics of 254 Patients with Difficult-to-manage Airways**

Characteristics	No. of Patients (N = 257)
Sex	
Female	107
Male	147
Mean age (range)	56 yr (11–89 yr)
Median weight (range)	72 kg (43–159 kg)
Median height (range)	172 cm (150–185 cm)
ASA physical status	
I	8
II	89
III	128
IV	24
IVE	6
VE	2
Location of procedure	
OR	246
ER	5
ICU	2
Radiology department	4
State of consciousness	
General anesthesia	200
Sedation and topical anesthesia	51
Unconscious	6

ASA = American Society of Anesthesiologists; E = emergency; OR = operating room; ER = emergency room; ICU = intensive care unit.

The *LMA-Fastrach*<sup>TM</sup> was used in patients during general anesthesia on 200 occasions (77.9%) and in patients during topical anesthesia and sedation in 51 cases (19.8%). On six occasions (2.3%), no anesthesia was used because the patients were unconscious.

The *LMA-Fastrach*<sup>TM</sup> was successfully inserted on the first attempt in 228 cases (88.7%), on the second attempt in 27 cases (10.5%), and on the third attempt in 2 cases (0.8%) (table 2). There were no failures to insert the device, and ventilation was possible in all patients.

Blind intubation through the *LMA-Fastrach*<sup>TM</sup> was attempted in 200 cases and was successful in 193 (96.5%). Blind intubation was achieved on the first attempt in 151 cases (75.5%). On the remaining blind intubation attempts, successful intubation was achieved on the second, third, fourth, and fifth attempts in 28 (14.0%), 7 (3.5%), 5 (2.5%), and 2 cases (1.0%), respectively. In seven cases (3.5%), blind intubation through the *LMA-Fastrach*<sup>TM</sup> failed after five attempts, and fiberoptically guided intubation was successful on the first attempt. In 57 cases, fiberoptically guided intubation was the initial intubating technique, with a 100.0% success rate on the first attempt. There were no pharyngeal, laryngeal, or esophageal complications associated with the use of the *LMA-Fastrach*<sup>TM</sup> in any of the patients included in this study.

#### *Patients in Whom Previous Intubation Techniques Had Failed*

According to the records we reviewed, in 111 cases (43.2%), previous intubations with a rigid laryngoscope

had failed, and the *LMA-Fastrach*<sup>TM</sup> was subsequently used emergently for intubation during general anesthesia on 23 occasions (20.7%) and electively as the primary intubating device in the remaining 88 cases (79.3%).

In the 23 cases in which the device was used emergently, intubation was performed blindly in 20 cases and with an FOB in 3 cases. Blind intubation was achieved on the first attempt in 15 cases (75%). Blind intubation was achieved on the second and third attempts in two cases (10.0%) each and on the fourth attempt in one case (5.0%). Fiberoptically guided intubations were successful on the first attempt in all three cases.

In 88 of 111 cases of patients with a history of failed intubation, the *LMA-Fastrach*<sup>TM</sup> was used electively with an overall success rate for blind intubation of 92.0% (n = 81). Blind intubation was achieved on the first attempt in 56 cases (63.6%). Successful blind intubation was achieved on the second, third, fourth, and fifth attempts in 15 (17.1%), 4 (4.5%), 4 (4.5%), and 2 cases (2.3%), respectively. In seven patients (8.0%), blind intubation failed, and intubation was completed successfully with the aid of an FOB. During FOB observation in these patients, three were found to have an epiglottis that was unusually narrow and omega-shaped and could not be lifted effectively by the EEB. In the other four patients, the epiglottis appeared soft and floppy, sliding off the EEB during blind intubation attempts and causing the ETT to slide over the epiglottis into the valleculae.

#### *Patients with Immobilized Cervical Spines*

The *LMA-Fastrach*<sup>TM</sup> was used in 70 cases (27.2%) of patients with unstable cervical spines that were immobilized in rigid Philadelphia collars. In 67 cases, insertion of the *LMA-Fastrach*<sup>TM</sup> and intubation were performed during general anesthesia. In two cases, topical anesthesia and sedation were used. One patient was unconscious, and no anesthesia was administered. Blind intubation was achieved on the first attempt in 63 cases (92.6%); in 5 cases (7.4%), two attempts were required. In two cases, elective fiberoptically guided intubation through the *LMA-Fastrach*<sup>TM</sup> was performed successfully. Of particular significance, no new neurologic deficits were observed secondary to airway management with the *LMA-Fastrach*<sup>TM</sup>.

The *LMA-Fastrach*<sup>TM</sup> was also used in 14 patients (5.4%) whose cervical spines were immobilized by previous surgical fusion. Blind intubation was successful in 13 patients: on the first attempt in 10 patients (76.9%), on the second attempt in 2 patients (15.4%), and on the third attempt in 1 patient (7.7%). In one patient, elective fiberoptically guided intubation through the *LMA-Fastrach*<sup>TM</sup> was performed successfully.

#### *Patients with Distorted Airways*

The *LMA-Fastrach*<sup>TM</sup> was used on 50 occasions (19.5%) in patients with distorted airway anatomies. In

Table 2. Success Rates for Insertion of and Intubation through the LMA-Fastrach™

Type of Procedure	No. of Attempts (%)					Failed
	1	2	3	4	5	
LMA-Fastrach™ insertion (n = 257)	228 (88.7)	27 (10.5)	2 (0.8)	—	—	—
Blind intubation through LMA-Fastrach™ (n = 200)	151 (75.5)	28 (14.0)	7 (3.5)	5 (2.5)	2 (1.0)	7 (3.5)
Intubation through LMA-Fastrach™ using an FOB						
After failed blind intubation (n = 7)	7 (100.0)	—	—	—	—	—
Elective FOB intubation (n = 57)	57 (100.0)	—	—	—	—	—

FOB = fiberoptic bronchoscope.

two patients with intrinsic tumors involving the airway, the LMA-Fastrach™ was used emergently after other methods of securing the airway had failed. In these patients, intubation through the LMA-Fastrach™ was achieved with an FOB. In eight patients, tumors caused extrinsic airway compression. In two of these patients, intubation through the LMA-Fastrach™ was performed blindly, with successful intubation achieved on the first attempt in one patient and on the second attempt in the other patient. In six patients with extrinsic airway compression, intubation was performed successfully through the LMA-Fastrach™ with initial use of an FOB. In all 40 patients with airway changes related to previous surgery, radiation therapy, or both, fiberoptically guided intubation was used electively and was successful through the LMA-Fastrach™.

#### Patients Wearing Stereotactic Frames

In 12 patients (4.7%) fitted with Leksell (Elekta Instruments Inc., Norcross, GA) or Compass (Regulus Corp., Rochester, MN) stereotactic frames, the LMA-Fastrach™ was used electively for airway management. In the first three cases, insertion was performed with the patient awake and during topical anesthesia, and intubation was achieved with fiberoptic guidance. In the remaining cases, insertion was performed during general anesthesia, and blind intubation was achieved on the first, second, and third attempts in six cases (50.0%), two cases (16.7%), and one case (8.3%), respectively.

#### The Chandy Maneuver

Both steps of the Chandy maneuver were applied in 73 of the 200 cases of patients in whom blind intubation through the LMA-Fastrach™ was attempted. For patients with all types of DA, the incidence of multiple intubations was significantly lower when the Chandy maneuver was used before intubation (4 of 73 [5%] vs. 41 of 127 [32%], odds ratio = 0.12, 95% confidence interval, 0.04-0.36 multiple intubation attempts,  $P = 0.0001$ ).

## Discussion

For patients with DA, the LMA-Fastrach™ combines the ventilatory benefits of the classic LMA™ with an

easier and more reliable method of tracheal intubation. The LMA-Fastrach™ can accommodate an ETT with an ID of up to 9.0 mm, and the device can easily be disengaged from the ETT when intubation has been completed.

The shape of the LMA-Fastrach™ is based on magnetic resonance imaging studies of the human airway, ensuring a close fit with the oropharyngeal curve and optimal alignment with the glottic opening when the head is maintained in a neutral position. Our results show that this design frequently permits successful and smooth blind passage of the ETT into the trachea. To reduce the risk of airway trauma associated with the use of blind intubation techniques, a special silicone ETT (maximum ID, 8.0 mm) has been developed by Dr. Brain and is recommended for use with the LMA-Fastrach™. This silicone tube has a low-volume cuff to minimize the risk of damage to it during intubation through the metal shaft of the LMA-Fastrach™. However, because silicone has different physical properties than do rubber and polyvinyl chloride, the use of this low-volume silicone cuff is not associated with the increased risk of high transmucosal pressure that is encountered with the use of these other materials.<sup>11</sup> An isolated case of esophageal perforation associated with intubation attempts through the LMA-Fastrach™ has been described,<sup>12</sup> but we found no evidence of esophageal or airway trauma associated with this device in 257 intubations.

Patients in whom intubation with a rigid laryngoscope fails often have a "high" or "anterior" larynx, which is classified as a Cormack-Lehane grade 4 view. Face mask ventilation may also be difficult in these patients and may further be compromised by soft tissue swelling from multiple intubation attempts. The consequence may be complete failure to perform ventilation in the patient, resulting in serious morbidity or death.<sup>1</sup>

In all 111 cases in our study in which rigid laryngoscopy, intubation, or both failed because of a Cormack-Lehane grade 4 view, insertion of the LMA-Fastrach™ and ventilation were successful. Although the success rate for first-attempt blind intubation in this group of patients was only 65.2%, within five attempts, it reached 92.0%. In seven patients, blind intubation failed, but intubation was successful with an FOB. Using fiberoptic

guidance during intubation through the *LMA-Fastrach*<sup>TM</sup> is very helpful, especially for an infrequent user of both devices. However, in situations in which an FOB may not be readily available, blind intubation through the *LMA-Fastrach*<sup>TM</sup> is a viable option and with experience can be performed successfully in a high percentage of patients. Regardless of the intubation technique used, the ability to perform successful ventilation in patients with the *LMA-Fastrach*<sup>TM</sup> was probably the biggest advantage of the device in this group of patients with DA.

All airway maneuvers cause some movement of the cervical spine.<sup>13,14</sup> In patients with cervical spine instability, the challenge is to select an intubation technique that minimizes the risk of further injury associated with airway manipulation.<sup>15</sup> The *LMA-Fastrach*<sup>TM</sup> is designed to be used while maintaining the patient's head and neck in a neutral position, and insertion of the device does not require any external manipulation of the patient's neck. Therefore, we hypothesized that the device should be safe to use in patients with unstable cervical spines who are wearing rigid Philadelphia collars.

In a 1999 study of human cadavers, Keller and Brimacombe<sup>16</sup> reported that pressure against the vertebrae of the cervical spine increased during *LMA-Fastrach*<sup>TM</sup> insertion, and they cautioned against using the device in patients with unstable cervical spines. However, there is no clinical evidence that the pressure changes described in the cadavers would result in significant cervical spine movement during *LMA-Fastrach*<sup>TM</sup> use. Kihara *et al.*<sup>17</sup> showed that in 20 patients with cervical spine pathology, *LMA-Fastrach*<sup>TM</sup> insertion and intubation with manual in-line stabilization were associated with only a 0.5- to 1.0-mm posterior displacement of C2-C5 vertebrae. These results are comparable with those of Hauswald *et al.*,<sup>13</sup> who found that fiberoptically guided oral and nasal intubations were associated with mean cervical spine movements of 1.78 and 1.08 mm, respectively. Indeed, based on the most recent cadaveric study by Brimacombe,<sup>18</sup> it seems that the *LMA-Fastrach*<sup>TM</sup> and the fiberoptic scope are the devices least likely to cause significant cervical spine movement when used for intubation.

There have been no reports of neurologic injury associated with the use of the *LMA-Fastrach*<sup>TM</sup> in patients with cervical spine pathology.<sup>19-21</sup> We used the *LMA-Fastrach*<sup>TM</sup> in 70 patients with unstable cervical spines, and none sustained a neurologic injury associated with the use of the device, despite the fact that in most of the patients, the instability involved the C2-C4 cervical vertebrae, which were closest to the *LMA-Fastrach*<sup>TM</sup> and most likely to be affected. Further experience with and controlled studies of airway management with the *LMA-Fastrach*<sup>TM</sup> in patients with unstable cervical spines are necessary to fully define the role of the device in these patients.

In the current study, insertions of the *LMA-Fastrach*<sup>TM</sup> were performed with the Philadelphia collar in place. However, Wakeling and Nightingale<sup>22</sup> studied the ease

of insertion and intubation through the *LMA-Fastrach*<sup>TM</sup> in healthy patients whose necks were immobilized with a different cervical collar (Stifneck Select; Laerdal Medical Corp., Wappinger's Falls, NY). They found it difficult to insert the *LMA-Fastrach*<sup>TM</sup> because the collar limited how wide the patient's mouth could be opened. They also stated that with the collar in position, the larynx seemed to have moved upward and forward, making it difficult to ventilate and impossible to intubate blindly through the *LMA-Fastrach*<sup>TM</sup>. After the collar was removed, blind intubation was successful in all patients in their study on the first attempt through the *LMA-Fastrach*<sup>TM</sup>. We observed a similar experience with the Stifneck Select collar in one patient with an unstable cervical spine who was not a part of this report.<sup>23</sup> Further research is necessary to determine how different rigid collar designs affect airway anatomy and which collar design is most suitable for use with the *LMA-Fastrach*<sup>TM</sup>.

Our data indicate that the *LMA-Fastrach*<sup>TM</sup> may also have a role in the ventilation and intubation of patients whose cervical spines have been immobilized by surgical fusion. In the 14 such cases presented in this article, *LMA-Fastrach*<sup>TM</sup> insertion, ventilation, and intubation were performed in all 14 patients during general anesthesia and without the use of a fiberoptic scope.

Intrinsic or extrinsic tumors involving the upper airway may cause significant anatomic distortion, making tracheal intubation difficult or impossible. In two patients who had general anesthesia with intrinsic tumors of the upper airway, rigid laryngoscopy and fiberoptically guided intubation failed, but ventilation and intubation with the *LMA-Fastrach*<sup>TM</sup> were successful. Although we do not recommend the primary use of supraglottic airways in patients with upper airway tumors, we found that the *LMA-Fastrach*<sup>TM</sup> may be useful in the emergency airway management of these patients when other techniques have failed.

In patients with airway distortion secondary to extrinsic compression, the *LMA-Fastrach*<sup>TM</sup> also proved useful in establishing ventilation. In one patient with a large goiter, there was significant tracheal deviation, and fiberoptic guidance with a bronchoscope 6.0 mm in diameter was used to achieve intubation through the *LMA-Fastrach*<sup>TM</sup>. Wakeling<sup>24</sup> reported a similar case in which intubation failed because the EEB of the *LMA-Fastrach*<sup>TM</sup> could not be lifted with a smaller fiberoptic scope.

In patients whose neck tissues have normal elasticity, insertion and inflation of the classic *LMA*<sup>TM</sup> and the *LMA-Fastrach*<sup>TM</sup> cause the soft tissues of the pharynx to expand outward. However, this expansion is limited in patients with tissue fibrosis resulting from previous neck surgery or radiation therapy, making correct positioning of the *LMA-Fastrach*<sup>TM</sup> more difficult. In our experience with 40 such cases, we found that in 10 patients, limited tissue elasticity required the use of a smaller *LMA*<sup>TM</sup>.

*Fastrach*™ than indicated by the patient's height and weight. We also used fiberoptic guidance during tracheal intubation. Indeed, our experience suggests that in patients with primary airway tumors or airway changes secondary to therapy, fiberoptic guidance should always be used when attempting tracheal intubation through the *LMA-Fastrach*™.

Airway management of patients undergoing stereotactic procedures may be difficult because access to the patient's airway is limited. A stereotactic frame interferes with face mask ventilation, and rigid laryngoscopy may not be feasible. We used the *LMA-Fastrach*™ electively in 12 patients fitted with Leksell or Compass stereotactic frames and found that after insertion of the *LMA-Fastrach*™, ventilation was achieved in all patients, and intubation was successful in all through the device.

After insertion of the *LMA-Fastrach*™, the optimal alignment of the device with the glottis cannot always be guaranteed. Applying the Chandy maneuver can be helpful in achieving optimal alignment of the device as reflected by a lack of resistance to bag ventilation. The best ventilating position tends also to be the best intubating position. In our hands, the use of the Chandy maneuver was associated with significantly higher rates of successful first-attempt blind intubations through the *LMA-Fastrach*™. However, the usefulness of this maneuver and its impact on the success rates for blind intubation through the *LMA-Fastrach*™ need to be studied further in a prospective manner.

## Conclusions

The limitation of this study is that our data are not comparative and, of necessity, unblinded. However, we have demonstrated the safe and effective use of the *LMA-Fastrach*™ in 254 patients with DA. Insertion of the *LMA-Fastrach*™ and intubation through it were successful on the first attempt in a high percentage of patients with various types of DA. This represents the largest analysis to date examining the use of the *LMA-Fastrach*™ in patients with DA, and success rates were similar to those reported in previous studies.<sup>5-7,17,19</sup> Our experience also demonstrates that the *LMA-Fastrach*™ may be a particularly valuable tool for the emergency or elective airway management of patients in whom other techniques have failed and in the treatment of patients with immobilized cervical spines.

The authors thank Kenneth R. Hess, Ph.D. (Associate Professor, Department of Biostatistics, The University of Texas M. D. Anderson Cancer Center, Houston, TX), for his assistance with the statistical analysis of data from this study.

## References

1. Caplan RA, Posner KL, Ward RJ, Cheney FW: Adverse respiratory events in anesthesia: A closed claims analysis. *ANESTHESIOLOGY* 1990; 72:828-33
2. Caplan R, Benumof JL, Berry FA, Blitt CA, Bode RH, Cheney FW, Connis RT, Guidry OR, Ovassapian A: Practice guidelines for management of the difficult airway: A report by the ASA Task Force on Management of the Difficult Airway. *ANESTHESIOLOGY* 1993; 78:597-602
3. Benumof J: The laryngeal mask airway and the ASA difficult airway algorithm. *ANESTHESIOLOGY* 1996; 84:686-99
4. Brain AJ, Verghese C, Addy EV, Kapila A: The intubating laryngeal mask. I: Development of a new device for intubation of the trachea. *Br J Anaesth* 1997; 79:699-703
5. Brain AJ, Verghese C, Addy EV, Kapila A, Brimacombe J: The intubating laryngeal mask, II: A preliminary clinical report of a new means of intubating the trachea. *Br J Anaesth* 1997; 79:704-9
6. Parr MJA, Gregory M, Baskett PJF: The intubating laryngeal mask airway use in failed and difficult intubation. *Anaesthesia* 1998; 53:343-8
7. Fukutome T, Amaha K, Nakazawa K, Nakazawa K, Kawamura H: Tracheal intubation through the intubating laryngeal mask airway (LMA-Fastrach) in patients with difficult airways. *Anaesth Intensive Care* 1998; 26:387-91
8. Brain AJ, Verghese C: *LMA-Fastrach*™ Instruction Manual. San Diego, LMA North America, 1998
9. Scanlon P, Carey M, Power M, Kirby F: Patient response to laryngeal mask insertion after induction of anaesthesia with propofol or thiopentone. *Can J Anaesth* 1993; 40:816-18
10. Cormack RS, Lehane J: Difficult tracheal intubation in obstetrics. *Anaesthesia* 1984; 39:1105-11
11. Young PJ, Burchewick K, Harvey I, Blunt MT: The prevention of pulmonary aspiration with control of tracheal wall pressure using a silicone cuff. *Anaesth Intensive Care* 2000; 28:660-65
12. Branthwaite MA: An unexpected complication of the intubating laryngeal mask. *Anaesthesia* 1997; 54:166-71
13. Hauswald M, Sklar D, Tandberg D, Garcia JF: Cervical spine movement during airway management: Cinefluoroscopic appraisal in human cadavers. *Am J Emerg Med* 1991; 9:535-8
14. Sawin PD, Todd MM, Traynelis VC, Farrell SB, Nader A, Sato Y, Clausen JD, Goel VK: Cervical spine motion with direct laryngoscopy and orotracheal intubation: An *in vivo* cinefluoroscopic study of subjects without cervical abnormality. *ANESTHESIOLOGY* 1996; 85:26-36
15. Hastings RH, Kelley SD: Neurologic deterioration associated with airway management in cervical spine-injured patients. *ANESTHESIOLOGY* 1993; 78:580-3
16. Keller C, Brimacombe J, Keller K: Pressure exerted against the cervical vertebrae by the standard and intubating laryngeal mask airways: A randomized, controlled, cross-over study in fresh cadavers. *Anesth Analg* 1999; 89:1296-1300
17. Kihara S, Watanabe S, Brimacombe J, Taguchi N, Yaguchi Y, Yamasaki Y: Segmental cervical spine movement with the intubating laryngeal mask during manual in-line stabilization in patients with cervical spine pathology undergoing cervical spine surgery. *Anesth Analg* 2000; 91:195-200
18. Brimacombe J, Keller C, Kunzel KH, Gaber O, Boehler M, Puhlinger F: Cervical spine motion during airway management: A cinefluoroscopic study of the posteriorly destabilized third cervical vertebrae in human cadavers. *Anesth Analg* 2000; 91:1274-8
19. Nakazawa K, Tanaka N, Ishikawa S, Ohmi S, Ueki M, Saitoh Y, Makita K, Amaha K: Using the intubating laryngeal mask airway (LMA-Fastrach) for blind endotracheal intubation in patients undergoing cervical spine operation. *Anesth Analg* 1999; 89:1319-21
20. Wong JK, Tongier WK, Armbruster SC, White PF: Use of the intubating laryngeal mask airway to facilitate awake orotracheal intubation in patients with cervical spine disorders. *J Clin Anesth* 1999; 11:346-8
21. Schuschnig C, Wald B, Erlacher W, Reddy B, Stoik W, Kapral S: Intubating laryngeal mask and rapid sequence induction in patients with cervical spine injury. *Anaesthesia* 1999; 54:793-7
22. Wakeling HG, Nightingale J: The intubating laryngeal mask airway does not facilitate tracheal intubation in the presence of a neck collar in simulated trauma. *Br J Anaesth* 2000; 84:254-6
23. Ferson D, Brimacombe J, Brain AJ, Verghese C: The intubating laryngeal mask. *Int Anesthesiol Clin* 1998; 36:183-209
24. Wakeling HG, Ody A, Ball A: Large goitre causing difficult intubation and failure to intubate using the intubating laryngeal mask airway: Lessons for the next time. *Br J Anaesth* 1999; 83:685-7